

LEFT VENTRICULAR ABNORMALITIES AMONGST HYPERTENSIVE PATIENTS IN YENAGOA, BAYELSA STATE; A REVIEW OF 100 ECHOCARDIOGRAMS

Kiridi E.K.¹ , Jesurobo D.E.² , Dambo N.D.³

- 1. Radiology Department, Federal Medical Centre, Yenagoa, Bayelsa State*
- 2. Internal Medicine Department, Federal Medical Centre, Yenagoa, Bayelsa State*
- 3. Directorate Of Clinical Services, Hospitals Management Board, Yenagoa, Bayelsa State*

CORRESPONDENCE

EMAIL: enefiakelvin@yahoo.com

ABSTRACT

Background

Abnormalities in left ventricular structure and function may occur in patients with systemic hypertension. These changes are a risk factor for acute cardiac events

Aim

We set out to describe the prevalence of abnormalities in left ventricular structure and function amongst hypertensive patients in Yenagoa, Bayelsa State.

Methods

This was a review of 100 echocardiograms of known hypertensive patients. Transthoracic 2D echocardiography was performed with patients in the left decubitus position using standard

techniques. Descriptive statistics were used to report data and tests of significance were carried out as appropriate. Level of significance was set at $p < 0.05$.

Results

The mean age of patients in this study was 51.20 ± 16.65 and 51% were males. Obesity was found in 27% of patients. The left ventricular mass and relative wall thickness were normal in 62% and 45% of patients respectively. About a third (31%) of patients had a normal cardiac geometry while concentric remodelling was seen in 31%. Concentric hypertrophy was noted in 24% and eccentric hypertrophy in 14% of patients. The ejection fraction was $>50\%$ in most (70/100) subjects and less than 40% in some (20/100). Obesity had a significant association ($p = 0.02$) with cardiac geometry. The body mass index did not have a significant association with the left ventricular mass (0.81) or the relative wall thickness (0.06). The left ventricular mass had a significant association with the ejection fraction (0.001) but there was no significant association between the relative wall thickness and the ejection fraction (0.40).

Conclusion

The findings of this study suggest that a lot of patients are at a risk of acute cardiac events and may benefit from health promoting regimens as well as counselling to follow their care plan.

KEYWORDS: Echocardiography, Hypertensive Patients, Yenagoa, Bayelsa, Left Ventricular Abnormalities

INTRODUCTION

Cardiac remodelling and abnormalities in function may occur following long standing hypertension and echocardiography plays a major role in the management of these patients^{1,2}. These changes in cardiac structure and function that occur from hypertension have been associated with significant morbidity and a risk of mortality^{3,4}.

The fact that hypertension is usually asymptomatic and the poor health seeking behaviour that has been documented³ in this environment, make a recipe for cardiac complications arising from hypertension to be a common occurrence.

Several authors in Nigeria have documented the abnormalities noted on echocardiogram amongst newly diagnosed hypertensive patients and those who have been on anti-hypertensive medication^{1,5-8}.

There is yet to be documentation of abnormalities found on echocardiography conducted on known hypertensive patients in Yenagoa, Bayelsa State.

MATERIALS AND METHODS

This was a review of 100 echocardiograms conducted between January 2013 and January, 2016. During this period, 370 echocardiograms were performed and 70 were found not to be suitable for the study as some of them had incomplete data and others had inter-observer bias. Of the 300 found to be suitable, 100 were randomly selected and data extracted for this study.

Each echocardiogram used for this study was conducted independently by both a consultant radiologist and a consultant cardiologist. Patients in this study were known hypertensive patients on medication who had been referred from various medical practices. Transthoracic

echocardiography was performed with patients in the left decubitus position using a two dimensional echocardiography on a 2012, Phillips HD 11 ultrasound machine. All measurements were carried out according to guidelines put forward by the American Society of Echocardiography and the European Association of Cardiovascular Imaging⁹.

Parameters assessed on echocardiography were the intra-ventricular septum diameter, left ventricular internal diameter, posterior wall thickness of the left ventricle. These were assessed during systole and in diastole. The diameter of the left atrium was measured in diastole and the function of the left ventricle was assessed by measuring the ejection fraction. Left ventricular function was classified into normal, mildly abnormal, moderately abnormal and severely abnormal² based on the ejection fraction of each patient. Though values are gender dependent², for this study, a normal ejection fraction was one between 52 and 72%, values between 41 and 51% were classified as mildly abnormal, 30-40% was moderately abnormal and less than 30% was severely abnormal.

The left ventricular mass was calculated using the formula¹⁰

$$\text{Left ventricular mass (LVM)} = 0.8 \times 1.04 [(LVIDd + PWTd + SWTd)^3 - LVIDd^3] + 0.6$$

Where

LVIDd = Left ventricle internal diameter in diastole

PWTd = Left ventricle posterior wall thickness in diastole

SWTd = Inter-ventricular septal wall thickness in diastole

The upper limit of normal for this study was taken as 235 grams^{11,12}

The relative wall thickness (RWT) was calculated from the formula¹⁰

$$\text{Relative wall thickness (RWT)} = 2(\text{PWT}) / \text{LVIDd}.$$

Relative wall thickness of 0.47 was taken as the upper limit of normal¹¹

Descriptive statistics and student's t-test were used for data reporting. Level of significance was taken as $p < 0.05$. Data were analysed using SPSS version 20

RESULTS

The age of patients ranged between 32 and 86 with a mean age of 51.20 ± 16.65 . Males constituted 51% (51/100) of the study population while 49% of the study population were females. Most of the participants (49/100) had a normal body mass index. Some (24/100) fell into the overweight category and (27/100) were obese.

The left ventricular mass was within normal limits in 62% (62/100) of patients, while the relative wall thickness was increased in 55% (55/100) of patients. Regarding the geometry of the heart, 31% had a normal geometry, 31% had concentric remodelling, 24% had concentric hypertrophy and 14% had eccentric hypertrophy. Obesity had a significant association with cardiac geometry ($p = 0.02$) with more obese patients 37% (10/27) having concentric remodelling and 33% (9/27) of the obese patients having concentric hypertrophy. The remaining obese patients had a normal cardiac geometry.

When the ejection fraction of patients was classified, 70% (70/100) had a normal ejection fraction, 10% (10/100) had mildly abnormal ejection fraction, 9% (9/100) had moderately abnormal ejection fraction and the remaining 11% (11/100) had severely abnormal ejection fraction.

There was a significant association between the left ventricular mass and the ejection fraction ($p = 0.001$) but not the relative wall thickness and the ejection fraction ($p = 0.40$)

The body mass index was not found to be predictive of either the left ventricular mass ($p = 0.81$) or the relative wall thickness ($p = 0.06$).

TABLE 1: FREQUENCY DISTRIBUTION OF PARAMETERS

PARAMETERS	NUMBER (X/100)	PERCENTAGE
SEX		
MALE	51	51
FEMALE	49	49
BODY MASS INDEX		
NORMAL	49	49
OVERWEIGHT	24	24
OBESE	27	27
LEFT VENTRICULAR MASS		
NORMAL	62	62
INCREASED	38	38
RELATIVE WALL THICKNESS		
NORMAL	45	45
INCREASED	53	53
EJECTION FRACTION		
NORMAL	70	70
MILDLY ABNORMAL	10	10
MODERATELY		

ABNORMAL	9	9
SEVERELY ABNORMAL	11	11

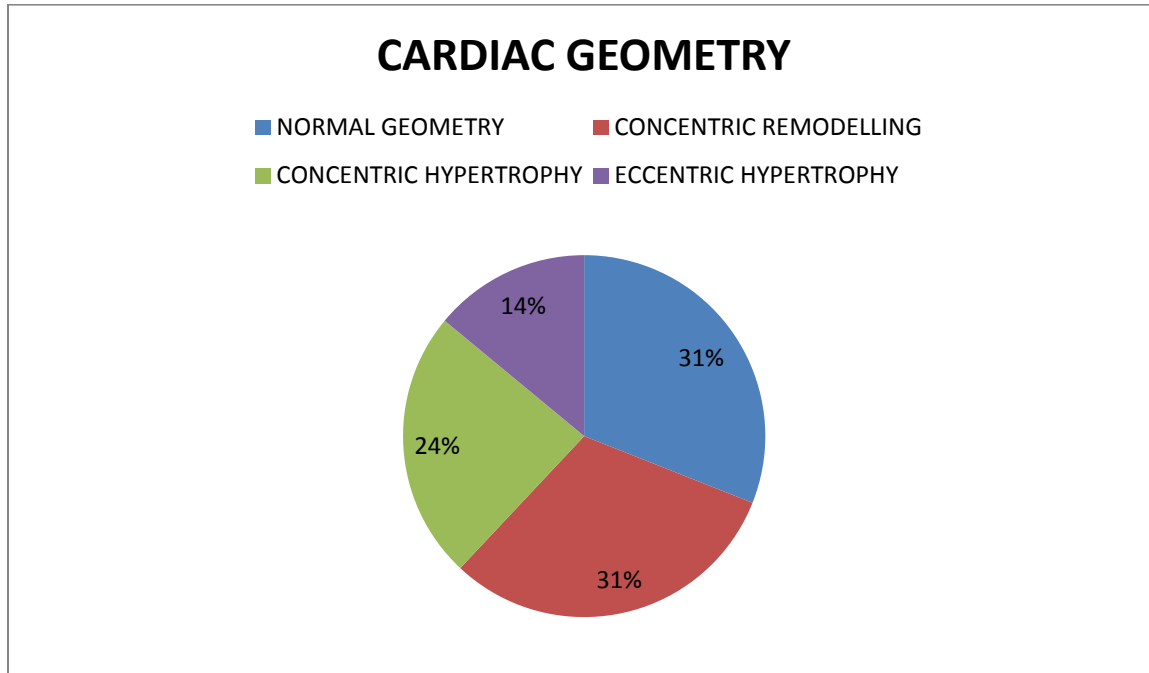
TABLE 2: CORRELATION WITH EJECTION FRACTION

PARAMETER	P VALUE
LEFT VENTRICULAR MASS	0.001
RELATIVE WALL THICKNESS	0.40

TABLE 3: CORRELATION WITH BODY MASS INDEX

PARAMETER	P VALUE
LEFT VENTRICULAR MASS	0.81
RELATIVE WALL THICKNESS	0.06

FIGURE 1



DISCUSSION

Worldwide, the guidelines for performing an echocardiogram differ⁴ and there is a need to define guidelines for the use of echocardiography in our environment considering that several cardiac morbidities have been described in newly diagnosed hypertensive patients^{1,8,13}.

This study has attempted to describe the pattern of cardiac abnormalities found in Yenagoa, Bayelsa state in a bid to provide better care to the people within this environment.

There was an equal distribution of sexes in this study and the mean age of patients in this study was 51.20 ± 16.65 . This age range is similar to the age range in other studies that have focused on newly diagnosed hypertensive people^{3,5,8,14}.

Obesity is thought to affect the heart by both direct and indirect mechanisms leading to abnormalities in structure and function of the heart¹⁵ and has been associated with an increase in the left ventricular mass and relative wall thickness². In this study, while the body mass index did not show a significant correlation with the relative wall thickness, left ventricular mass or cardiac geometry, obesity showed a significant association with cardiac geometry ($p = 0.02$). The findings in this study of more obese patients having concentric remodelling of the heart followed by concentric hypertrophy is in keeping with the findings of Ajayi and colleagues¹⁵ from their work on obese patients in Ekiti, Nigeria.

More patients in this study had a normal left ventricular mass while less had a normal relative wall thickness. Age, ethnicity, gender, environmental factors, duration and treatment of hypertension are known to affect these parameters² hence the need for local studies to define what is normal for our environment. The values used in this study were those obtained from controls in a study carried out in Nigeria that attempted to determine the effect of having hypertensive parents on cardiac parameters. The paucity of data regarding echocardiography in this environment has been highlighted^{1,5,15} and needs to be addressed. From these, it is seen that only about a third of the patients have a normal cardiac geometry. Another third were found to have concentric remodelling which is known to be a response of the left ventricle to chronic pressure, volume overload or myocardial infarction and may be seen in long standing untreated hypertension². Patients with concentric hypertrophy and eccentric hypertrophy were noted in this study. From the reviewed literature^{1,6,8,13}, there does not to be any particular pattern to the occurrence of these abnormalities in cardiac geometry though the concentric forms of remodelling appear to be more common. Patients should however be taught that the presence of

an abnormal cardiac geometry is an independent risk factor for cardiovascular events⁸ and encouraged to follow their management plan to reduce their risk of morbidity.

An ejection fraction of less than 40% was seen in 20% of patients in this study. Ejection fraction is a marker of left ventricular function and these patients are thought to be in systolic heart failure². The left ventricular mass was significantly associated with the ejection fraction ($p = 0.00$) while the relative wall thickness did not show an association with the ejection fraction ($p = 0.40$). This finding may be because in calculating the left ventricular mass, the thickness of the interventricular septum is considered in addition to the posterior wall thickness and internal diameter of the left ventricle unlike the relative wall thickness which considers only the posterior wall thickness and internal diameter of the left ventricle. This may mean that the left ventricular mass is a more sensitive predictor of cardiac geometry as regards function when compared to the relative wall thickness. This will need to be validated by further studies.

This study has shed some light on the abnormalities in left ventricular parameters in known hypertensive patients. We hope that it can help clinicians in counselling their patients as regards compliance to their care and also assist in designing health promotion programs for hypertensive patients in this environment.

REFERENCES

1. Aje A, Adebisi AA, Oladapo OO, et al. Left ventricular geometric patterns in newly presenting Nigerian hypertensives : An echocardiographic study. *BMC Cardiovascular Disorders* 2006;6(Lv):1-6. doi:10.1186/1471-2261-6-4.
2. Marwick TH, Gillebert TC, Aurigemma G, et al. Recommendations on the Use of Echocardiography in Adult Hypertension : A Report from the European Association of Cardiovascular Imaging (EACVI) and the American Society of Echocardiography (ASE) †. *J. Am. Soc. Echocardiogr.* 2015;28(7):727-754. doi:10.1016/j.echo.2015.05.002.
3. Egbi OG, Okafor UH, Meibodei KE, Kunle-olowu OE, Unuigbo EI. Prevalence of Hypertension in an Urban Population in Bayelsa State , *J Med Res Pract.* 2013;2(1):11-15.
4. Lee J, Park J. Role of echocardiography in clinical hypertension. *Clin. Hypertens.* 2015:1-11. doi:10.1186/s40885-015-0015-8.
5. Gu A, Ai K, Opadijo GO, Abo O, Am A. Prevalence of left ventricular diastolic dysfunction in newly diagnosed Nigerians with systemic hypertension : a pulsed wave Doppler echocardiographic study. *African Health Sciences* 2010; 10(2) :177-182.
6. Akintunde AA, Familoni OB, Akinwusi PO, Opadijo OG. Cardiovascular Topics Relationship between left ventricular geometric pattern and systolic and diastolic function in treated Nigerian hypertensives. *Cardiovasc J Afr* 2010;21(1):21-25.
7. Adebayo RA, Bamikole OJ, Balogun MO, Akintomide AO. Clinical Medicine Insights : Cardiology Echocardiographic Assessment of Left Ventricular Geometric Patterns in Hypertensive Patients in Nigeria. *Clinical Medicine Insights: Cardiology* 2013;7 161–167
8. Isa MS, Bala GS, Oyati AI, Danbauchi SS. Patterns of left ventricular hypertrophy and geometry in newly diagnosed hypertensive adults in Northern Nigerians. *J. Diabetes Endicrono.* 2010;1:1-5.
9. Lang RM, Badano LP, Mor-avi V, et al. Recommendations for Cardiac Chamber Quantification by Echocardiography in Adults : An Update from the American Society of Echocardiography and the European Association of Cardiovascular Imaging. *J. Am. Soc. Echocardiogr.* 2015;28(1):1-39.e14. doi:10.1016/j.echo.2014.10.003.
10. Hristova K, Shiue I. The Role of Echocardiography for Evaluation Patients with Arterial Hypertension. *Ann Clin Exp Hypertension .* 2015;3(1)1016
11. Kolo P, Sanya E, Ogunmodede J, Omotoso A, Soladeye A. Normotensive offspring of hypertensive Nigerians have increased Left ventricular mass and abnormal geometric patterns mass and abnormal geometric patterns. *Pan African Medical Journal.* 2012; 11:6

12. Schvartzman PR, Fuchs FD, Mello AG, et al. Normal Values of Echocardiographic Measurements . A Population-Based Study. *Arq Bras Cardiol*, 2000;75(2):111-114.
13. Adeoye AM, Adewoye IA, Adebisi A, et al. Original Article The relation of gender and geometry to left ventricular structure and functions in a newly presenting hypertensive population in Nigeria. *Nigerian Journal of Cardiology*2015;12(2):136-141. doi:10.4103/0189-7969.161777.
14. Azubuikwe SO, Kurmi R. Awareness , practices , and prevalence of hypertension among rural Nigerian women. *Arch Med Health Sci* 2014;2(1):23-28. doi:10.4103/2321-4848.133791.
15. Ajayi EA, Ajayi AO, Ajayi IA, Adegun PT, Adeoti OA, Omotoye OJ. Echocardiographic Left Atrial and Ventricular Structural Changes in Nigerian Obese Hypertensive Patients seen in Clinical Practice. *Journal of Cardiovascular Disease Research*2014;5(2):3-8. doi:10.5530/jcdr.2014.2.10.